

Headache

Associated with Acoustic Neuroma Treatment

INTRODUCTION

Advances in the management of acoustic neuroma have reduced both the associated surgical mortality and morbidities (e.g., facial nerve paralysis, cerebrospinal fluid leak, meningitis). However, head pain is expected in most patients immediately after acoustic neuroma surgery (acute phase) because of the incision, variations in cerebrospinal fluid pressure, muscle pain, or even meningitic pain. It typically responds to appropriate medications and resolves within several weeks.

Headache that persists for months or even years after surgery (chronic phase) can be debilitating and may be an under-appreciated complication of acoustic neuroma treatment. The International Headache Society added a classification of post-craniotomy headache not related to trauma (acute and chronic – see table on Page 14). This definition clarifies both to patients and physicians the nature of the post-surgical pain. While chronic headache may occur in patients after any type of craniotomy, the incidence of headache following acoustic neuroma surgery has been noted for many years to be higher than after craniotomy for other causes.

The exact prevalence and causes of chronic postoperative headache (POH) are elusive. There are several reasons for this. First, the reporting of factors that affect quality of life rather than mortality and objective signs of morbidity is a relatively recent phenomenon. Second, headaches are common in the general population at baseline, and they are often different from patient to patient and not easily classifiable. And, third, reports from dedicated headache centers rarely offer significant detail regarding operative approach or nuances, while reports from individual surgical centers cannot be said to be generalizable to the population of acoustic neuroma patients as a whole. Also, the experiences and biases of surgeons and others involved in the treatment of acoustic neuromas often lead them to radically different opinions and conclusions regarding the issue of headache in acoustic neuroma patients.

After surgical treatment of acoustic neuroma, the reported incidence of headache in the 2007-2008 ANA patient survey ranged from 0% to 33% depending on the type of surgical approach, technique used and reporting interval since surgery. Frequent and severe POHs have been more often associated with the sub-occipital or retrosigmoid approaches than the translabyrinthine or middle fossa approaches.

Preoperative headaches attributed to the acoustic neuroma alone are relatively uncommon. According to the data generated by the 1998 ANA patient survey, headache sufferers of other causes (migraine, tension headache and even fibromyalgia) rarely have significant exacerbations due to surgical removal of the tumor. In patients who experience chronic POH, the pain often persists for prolonged periods of time, and does not always respond well to various medical and surgical treatments. Publications in the past including ANA surveys in 1983,

1998 and 2007-2008 and subsequent analyses have increased treating physicians' awareness of the impact of headaches on recovery from acoustic neuroma treatment; improved their ability to accurately counsel patients preoperatively; and as a result, several preventative techniques have been proposed. This summary will provide an overview of headaches following acoustic neuroma surgery, including their frequency, the nature of the headache, their causes and current therapies.

FREQUENCY OF HEADACHE FOLLOWING ACOUSTIC NEUROMA SURGERY

Several well-respected large medical centers have published their experience with POH, however, the majority of these studies were fraught with few study patients, and a lack of standardized definitions and reporting. By far, the two largest series to date are both ANA patient surveys from 1998 and 2007-2008. When interpreting these series, however, it should be noted that responses have not been verified and that the group of patients who chose to respond may not represent all acoustic neuroma patients as a whole.

The 1998 survey results were analyzed and presented to treating physicians at a national conference in 2004. In this survey there were 1,940 respondents, of which 1,675 members underwent surgical removal of their acoustic neuromas. Of these, nearly 700 (41%) answered detailed questions categorizing their POH and its impact on their quality of life. In the analysis all responses were stratified by tumor size, surgical approach, member's age and gender. Numerous significant relationships were found. The following details pertain to these 700 member responses.

In general, preoperative headache (not necessarily attributed to the tumor) was reported in about one-third of respondents and was more frequent in patients with larger tumors. Analysis did not reveal any significant difference in their POH measures compared to patients without preoperative headache. Postoperative headaches of any kind developed within the first month in 75% of members. Worsening headache developed in 56.2% while in the hospital, 27.3% within 6 months postoperatively and in 16.5% more than 6 months postoperatively.

Early resolution of acute POH (<12 weeks) occurred more commonly with the translabyrinthine approach and in male patients. Chronic POH (>12 weeks) was reported in 88% (609) of respondents. By one year the incidence of chronic POH was similar for all surgical approaches, with the retrosigmoid approach having the highest rate early on. Sixty-four percent of respondents at the time of survey still had some degree of ongoing headache; of these the majority felt it was improving (74%). Typical POHs occurred more than once daily (46%), lasted 1 to 4 hours in duration (43.1%), and were of moderate intensity (62.6%). The majority (78%) of patients rated their worst headaches as "severe." The treatment most often reported for typical headaches were non-prescription medications including nonsteroidal anti-inflammatory drugs (NSAIDs) in 61.3%, and regular use of narcotics in only 15%. About half of the patients were able to work during a

typical headache. Patients were half as likely to report being able to work after having had a retrosigmoid approach, as were patients after translabyrinthine and middle fossa approaches. Women and younger patients tended to have poorer outcomes with regard to POH. Tumor size was not significantly related to any of the POH measures.

In the 2007-2008 patient survey by ANA, there were 2,004 respondents, of which 61% underwent surgical removal of their acoustic neuromas, 22% reported having radiation treatment and 20% were watch and wait patients. Similar to the 1998 survey, 33% of the respondents reported issues with headaches. See the chart below for detailed information received from respondents.

2007-2008 AN Patient Survey

Symptoms*	Microsurgery 39%		Single Dose Stereotatic Radiosurgery 31%		Fractionated Stereotatic Radiotherapy 23%		Watch & Wait 22%	
	Initial Onset	Time of Survey	Initial Onset	Time of Survey	Initial Onset	Time of Survey	Initial Onset	Time of Survey
Constantly	21%	9%	12%	10%	26%	10%	9%	12%
Daily	28%	19%	41%	23%	31%	21%	27%	26%
Weekly	27%	20%	24%	25%	28%	36%	29%	34%
Monthly	11%	15%	12%	18%	5%	13%	15%	6%
Less Frequent than once a month	6%	16%	6%	13%	3%	5%	13%	11%
No Longer experience headaches	1%	20%	0%	11%	0%	15%	0%	10%
Severity Scale								
10 (Most Severe/Disabling)	17%	1%	6%	4%	8%	0%	6%	6%
9	12%	4%	5%	1%	5%	3%	7%	0%
8	14%	4%	18%	8%	13%	0%	9%	5%
7	15%	6%	18%	4%	15%	0%	10%	5%
6	10%	13%	10%	11%	18%	21%	13%	16%
5	10%	14%	14%	13%	5%	3%	20%	20%
4	6%	12%	20%	14%	13%	18%	7%	10%
3	10%	15%	6%	14%	10%	33%	12%	18%
2	3%	14%	1%	20%	10%	15%	7%	9%
1	4%	17%	1%	10%	3%	8%	9%	12%

*Symptoms experienced at any time related to AN

It is thought that modifications of several aspects of microsurgical procedure, as described below, have produced a significant reduction of persistent headaches after acoustic neuroma surgery in some patients.

TYPES OF POST ACOUSTIC NEUROMA SURGERY HEADACHES

Headaches that occur after acoustic neuroma surgery can be quite varied in their type, but may share certain characteristic symptoms. Nearly all patients initially experience some degree of headache and incision pain related to craniotomy, partly due to head positioning during surgery. This pain can be a sharp or searing pain at the incision site, with associated stiffness and spasm of the neck muscles and an aching, throbbing headache. These symptoms are not significantly different from the kinds of headaches which occur in the first few weeks following any other cranial surgical procedure.

Post acoustic neuroma surgery headaches, however, differ from the usual post-surgical headaches in several respects. Beginning two to three weeks after surgery, at the time that the craniotomy headache is often subsiding, patients after acoustic neuroma surgery frequently note progressively increasing aching and tenderness, which seems to be localized in the area of the incision. Occasionally the pain spreads from this site to the entire head, and many patients describe a pressure sensation encircling the skull. Often, the neck muscles are stiff and tender, and head movements or physical activity can initiate severe spasms or shock-like sensations which radiate up into the back of the head or down into the neck and shoulder. A characteristic feature of these headaches is that they are precipitated by coughing or sneezing which can trigger a severe, unremitting headache lasting for hours or days.

In most patients, the headaches are constant, although they wax and wane with occasional, intense, incapacitating pain. As above, the majority of these headaches subside over time, but a significant proportion persists for years after surgery. In some cases there appears to be an exceptional sensitivity of nerves in the region of the incision, with associated numbness over the back of the skull and occasional electric shock-like pains caused by pressure on the incision.

RADIOSURGERY AND HEADACHE

Several studies regarding efficacy and complications of radiosurgery (or stereotactic radiotherapy) for acoustic neuroma, reported new onset headache incidence between 0 and 8%. No specific studies on post-radiosurgery headache exist. However, post-radiosurgery trigeminal neuralgia can occur whether transient or persistent. The incidence is between 3 to 8%, and is likely related to the unintentional dose of radiation received by the nerve. Ironically, radiosurgery has been shown to be an effective treatment for primary trigeminal neuralgia, typically resulting in facial numbness. In the experience of most practitioners, the incidence of headaches after radiosurgery is low. However, these data have not been carefully studied, and it should not be assumed that this is necessarily true.

WATCH AND WAIT AND HEADACHE

Some patients in the watch and wait group with acoustic neuromas also report significant headache. It should be noted that only 2% of all people report having no incidence of headache during their lifetimes. Headaches of other causes not related

directly to the tumor may be the most important factor in this group. However, it should also be noted that disruption of normal vestibular function may alter vestibulo-cervical reflexes, influencing neck muscle tension and the occurrence of resulting headaches.

POTENTIAL CAUSES OF POST ACOUSTIC NEUROMA SURGERY HEADACHE

Several precipitating factors have been put forth as potential causes for headaches which occur following acoustic neuroma surgery. Although the specific causes of these headaches remain unknown, recent studies have shed light on various factors which might contribute to the pain. The results of these studies have also provided potential strategies for prevention and treatments for these headaches. In summary, many factors may contribute to the occurrence of pain after acoustic neuroma surgery, some of which likely are preventable.

MICROSURGICAL APPROACH

Considerable controversy remains concerning the relationship of the surgical approach employed to the occurrence of post-surgical headache (Figure 1). In the acoustic neuroma literature there is no question that the risk of headache is highest with the retrosigmoid/sub-occipital (retrosigmoid) approach. It may be the way the dura or the defect is repaired across the country, but it might also be the positioning of the patient. In a retrosigmoid approach the patient's head is turned to the side, and it is the most posterior to anterior approach (more from the back). A significant extension on the patient's neck is necessary in order to expose the internal auditory canal. With the translabyrinthine and middle fossa approaches, it is more of a lateral to medial access to the internal auditory canal (more from the side). It is also the incision that puts that occipital nerve at greatest risk and requires the most stripping down of the cervical spine musculature that attaches to the occipital bone.

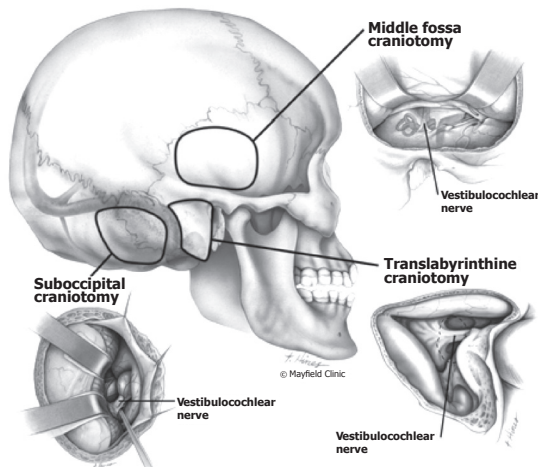


Figure 1. The surgical approaches to an acoustic neuroma: retrosigmoid/sub-occipital, translabyrinthine, and middle fossa. (Printed with permission Mayfield Clinic - www.mayfieldclinic.com)

CRANIOTOMY, CRANIECTOMY, CRANIOPLASTY

Craniotomy means to cut an opening in the skull, and craniectomy means to remove a piece of the skull. The cut piece of bone removed with a craniotomy is called a bone flap. In either case, the resulting hole exposes the dura, which is the extremely sensitive covering of the brain. After tumor removal, the skull opening can be closed in a variety of ways. If a craniectomy is performed, without any attempt at repair, the bone flap is not replaced and the soft tissues (muscles, skin) are closed directly over the dura. If a craniotomy is performed, the bone flap is returned to its original position and can be secured in place with small plates and screws. A cranioplasty is repair of the skull with material other than the bone flap, such as more extensive titanium plate or mesh or synthetic bone substitute. A cranioplasty may be used to repair a craniectomy defect or to fill in spaces around a bone flap, since even with craniotomy the bone flap may be substantially smaller than the resulting hole in the skull.

In the early nineties several authors hypothesized that headaches occurred following a craniectomy when cervical muscles scarred or adhered to the pain-sensitive dura. They presumed that replacing the bone or an equivalent barrier between the dura and the muscles could prevent those headaches. Harner found that patients with a plastic cranioplasty had a 4% incidence of headache at 3 months compared to 17% in those without. Fegahli described a split-calvarial cranioplasty (borrowing bone from a different part of the skull) in which 5% had persistent headache beyond one year. Wazen et al., compared 30 patients with titanium-plastic cranioplasty to a matched group without such. Although the frequency of headaches in the two groups was equivalent, patients with cranioplasty had significantly less severe headaches.

ASEPTIC MENINGITIS

Aseptic means “without bacterial infection,” and meningitis means “inflammation or irritation of the meninges (dura) covering the brain.” As noted above, the meninges are intensely pain-sensitive, and aseptic meningitis from a variety of causes frequently produces severe headaches with many characteristics similar to those occurring in patients after acoustic neuroma surgery. Several aspects of intracranial tumor surgery can predispose a patient to aseptic meningitis, including blood and protein in the spinal fluid, traction and incision upon the meninges and prolonged exposure of the meninges to the environment during surgery. However, these factors frequently are present in numerous other intracranial operations which are not associated with such severe headaches.

One factor which is particular to acoustic neuroma surgery is drilling of bone from within the intradural space (after incising the dura to access the tumor), for further exposure of the tumor in the internal auditory canal. The resulting bone dust often is distributed around the meninges in the posterior fossa, and can be difficult to remove completely. Intradural drilling is nearly exclusive to the retrosigmoid approach for acoustic neuroma removal, and much less common in the translabyrinthine or middle fossa approaches. Two studies have highlighted the importance of bone dust in inducing aseptic meningitis after acoustic neuroma surgery.

Jackson et al., compared headaches for two procedures that utilize a retrosigmoid craniotomy. The first was for acoustic neuroma surgery the other for vestibular nerve section, which is essentially an identical procedure without intradural bone drilling. Whereas 54% of patients with acoustic neuroma surgery had headaches, only 5% of patients with vestibular nerve sectioning had headaches. This issue was more directly investigated by Catalano et al., who compared the effects of cranioplasty and meticulous trapping and removal of bone dust residue in acoustic neuroma surgery. In this study, performing a cranioplasty did not reduce headaches, but bone dust removal had a profound effect upon the incidence of postoperative headaches. Since the publication of these data, measures taken to substantially reduce the distribution of bone dust within the spinal fluid during the surgery seem to have caused a reduction in postoperative headaches in some patients.

MUSCLE PAIN

Myalgia is a non-specific term, which refers to pain emanating from the muscle. The neck muscles are extremely pain sensitive, and the pain from the cervical muscles frequently is perceived in the back part of the head. Tension headaches are a very common form of headaches which are attributed to stress, producing tightness or spasm in the neck muscles, manifested as headache affecting the back of the head. Many features of post-surgical acoustic neuroma headaches are consistent with this type of head pain, which is localized to the site of surgery, including tenderness and spasm of the muscles and is worsened by stress or physical activity. Depending on the surgical approach and specific incision utilized, neck and/or temple region muscles are typically cut to expose the skull. Minimizing incisions in the neck muscles appears to have reduced the incidence of headaches in some patients. It should be noted that a smaller skin incision does not necessarily imply a lesser amount of neck muscle dissection and that often a well-planned larger incision may allow for less muscle dissection. Therapy directed at cervical muscle pain and spasm is often effective in reducing headache after acoustic neuroma surgery.

NERVE ENTRAPMENT

The occipital nerve typically lies in the field of surgery in the retrosigmoid approach, and supplies nerves to the skin on the back of the head. This nerve can be cut, stretched or trapped in the scar tissue from surgery and may become hypersensitive (Figure 2). The electric-shock pain associated with acoustic neuroma headaches may be related to involvement of this nerve. However, therapies directed toward the occipital nerve such as nerve block injections have not been uniformly successful. Some surgeons have found that by using a high-arching or otherwise curved skin incision, like the one depicted in Figure 2B, the lesser occipital nerve is less likely to sustain damage during surgery and thus less likely to cause postoperative headache.

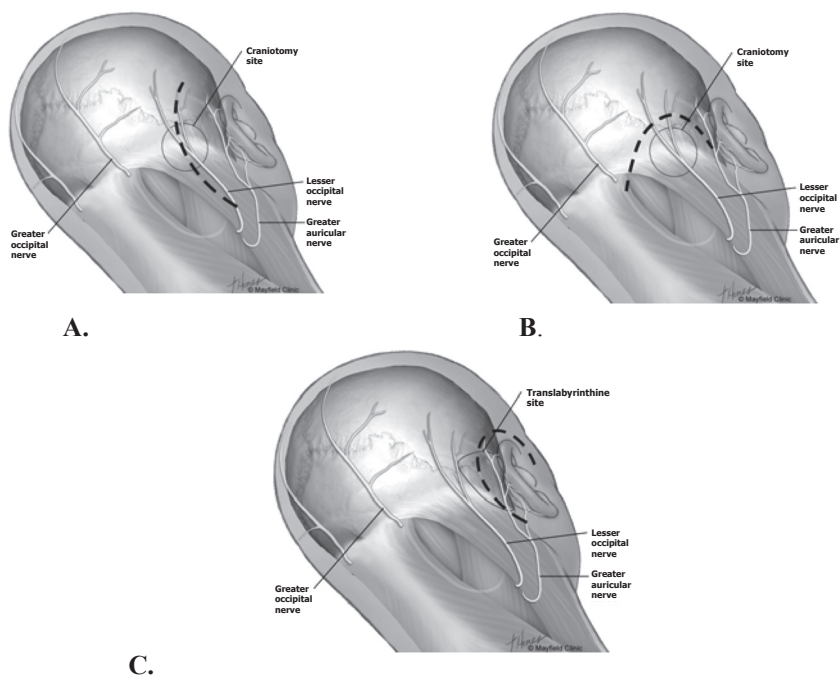


Figure 2. Postoperative headache can be caused by damage to the occipital nerves during skin incision and muscle retraction. Complete cutting of the nerve branches causes numbness of the posterior scalp. On the other hand, partial injury or entrapment of the nerves from instruments and muscle retraction can cause neuroma formation leading to headache pain. **A.** The traditional straight skin incision for the retrosigmoid approach causes greater disruption to the lesser occipital nerve deep in the neck muscles. In addition, dissection of the muscles deep in the neck may lead to significant and protracted neck muscle pain. **B.** The alternative high-arching or otherwise curved skin incision crosses the nerve branches peripherally and avoids deep dissection of the neck muscles. This type of skin incision is less likely to cause postoperative headache. **C.** The C-shaped skin incision for the translabyrinthine approach avoids deep dissection of the neck muscles and is less likely to cause postoperative headache. (*Printed with permission Mayfield Clinic www.mayfieldclinic.com*)

LOW CEREBROSPINAL FLUID PRESSURE

During the course of surgery an intentional cerebrospinal fluid (CSF) leak is created and excess fluid is removed to allow visualization in the surgical field. A persistent CSF leak, or failure to replace some of the fluid at the end of the procedure, can initially produce severe headaches that are typically worse when sitting, standing or straining. However, usually there are additional manifestations of a CSF leak, and it is unlikely that a leak would go undetected for months.

THERAPEUTIC OPTIONS

The best treatment for headaches occurring after acoustic neuroma surgery almost certainly is prevention, since these headaches have proven difficult to treat once they occur. Nevertheless, with increasing recognition of these headaches, additional treatment strategies have been reported with encouraging results. In general, if headache is not prevented, or the exact source of pain not treated at the initial onset (steroids for aseptic meningitis, etc.), there is potential for a more prolonged recovery. The majority of chronic postoperative headaches improve with time, but in the interim the perception of the pain can be altered with various techniques, however, patients' success with any given treatment may differ.

Unfortunately, there are no well-designed studies specific to the post-craniotomy headache population. Thus physicians need to infer from studies for more common types of headache (migraine, tension, chronic daily headache) to guide their treatment strategies. Regarding complementary or Eastern Medicine derived treatments, if a patient is able to achieve notable, consistent relief from a non-invasive or minimal risk therapy, at a reasonable cost, it may be beneficial even if not clinically proven.

SURGERY - REVISION CRANIOPLASTY

A number of reports have described secondary cranioplasty as a treatment for headaches in patients who had craniectomy without repair at the initial surgery. In this procedure the bony opening is re-exposed and covered with titanium, synthetic material, or, less often, a graft of skull bone taken from another site. The reports to date are largely anecdotal without good control comparisons, although there are numerous reports of dramatic improvement in headache in individual patients. The disadvantage of this therapy is that it requires another operation, though the procedure is not nearly as extensive as the original surgery.

NERVE BLOCK OR SECTION

As above, trapping of the occipital nerve has been implicated at the onset of acoustic neuroma post-surgical headache. However, in many cases, injection or surgical division of the nerve has not been particularly successful. These therapies should be reserved for those patients for whom there is distinct pain or other symptoms typical of nerve entrapment.

HEADACHE MEDICATIONS - ACUTE PHASE

The majority of headaches occurring after acoustic neuroma surgery are treated by various medications. Because inflammation (either in the meninges or muscle) plays a large role in the origin of the pain in the first weeks to months, anti-inflammatory agents are the most common forms of treatment. Corticosteroids (Prednisone, Dexamethasone) are very potent anti-inflammatory agents, and produce dramatic improvement in the headache in a large percentage of cases. However, corticosteroids have profound long-term ill effects, and should not be taken for longer than a few weeks at a time. Corticosteroids can be particularly effective when given at the early stage of onset of post-surgery acoustic neuroma

headaches, i.e., within the first few weeks after surgery. Some physicians typically prescribe an initial high dose followed by a gradual taper over two weeks, at which time a transition to nonsteroidal anti-inflammatory drugs is prescribed.

Nonsteroidal anti-inflammatory drugs (NSAIDs) are the mainstay of therapy for headaches occurring after acoustic neuroma surgery. There are a variety of these agents available over the counter (Ibuprofen, Naprosyn), and they generally can be taken safely for prolonged periods of time. Some physicians recommend that patients take these drugs at higher doses (e.g., Ibuprofen 600mg three or four times daily) on a continuous basis, even when the headache is not severe. The treatment is continued for several weeks and then gradually stopped. A clinical trial substantiated the efficacy of nonsteroidal anti-inflammatory drugs, and also noted the potential efficacy of two additional drugs (Divalproex sodium and Verapamil) in patients who fail this treatment. The major potential side effects of nonsteroidal anti-inflammatory drugs are upset stomach and stomach bleeding. Excessive doses beyond the recommended limits may be associated with kidney injury. Muscle relaxants often may serve as a helpful adjunct to treating neck muscle spasm. These drugs could be habit-forming or decrease in effectiveness over time.

HEADACHE MEDICATIONS - CHRONIC PHASE

Medications used for chronic headaches are aimed at lessening the perception of pain while minimizing the adverse reactions. They do not necessarily treat the origin of the pain (as do steroids in the acute phase). Low dose antidepressants such as Nortriptyline and Amitriptyline have been proven to be effective additions to other treatments. If depression is present they can be taken at higher doses, however, with potential for an increase in adverse effects such as dry mouth or urinary difficulty.

Anticonvulsants such as Neurontin or Valproic Acid are being used more commonly to treat chronic pain. A review of multiple randomized placebo controlled trials was conducted by the Cochrane Pain, Palliative and Supportive Care Group looking at the use of Neurontin to treat acute and chronic pain for conditions such as post-herpetic neuralgia, diabetic neuropathy, phantom limb pain and others (none were specific for post craniotomy pain). In this study approximately 42% reported improvement while taking Neurontin compared to only 19% on placebo. It was ineffective for acute pain. Another study by Spira et al., in 2003, found a 9% improvement in achieving headache-free days with Neurontin compared to placebo in patients with chronic daily headache.

Finally, in a randomized study by Mathew et al., looking at Neurontin to treat migraine sufferers, they reported a significant reduction in migraine rates compared to placebo with the most common side effect being drowsiness and dizziness. Thus, Neurontin may be beneficial to treat headache and chronic pain, as long as the side effects are tolerable. Recent anecdotal information is now available that Topamax can be effective in treating headache associated with acoustic neuroma.

BOTOX®

In recent years Botulinum Toxin (Botox®) injections have been used to treat various types of headaches (migraine, tension headaches, chronic daily headache, etc.). Anecdotal and “open labeled” trials reported positive responses. However, reviews of the literature of randomized placebo-controlled trials suggest that the placebo effect is significant, and further studies are required to determine if Botox offers any additional benefit over placebo. It should be noted that these studies were conducted in people who never had injury to their head and neck musculature, unlike acoustic neuroma patients. Thus localized injections into the musculature in the region of the craniotomy may offer a benefit for acoustic neuroma patients.

LOCAL THERAPY TO NECK MUSCLES

In cases of headache resistant to medical treatment, local therapy applied to the neck muscles may be effective in many cases. This includes physical therapy with stretching and range-of-motion exercises, local heat application, massage and biofeedback to learn muscle relaxation techniques. On occasion, a “trigger point” can be identified in the cervical muscles which appear to be a source of pain and tenderness. Local injection of an anesthetic or steroid at this site can occasionally provide substantial temporary relief of pain.

A study by van Ettehoven reported significant improvement in treating tension headache with craniocervical training program (CTP) (low load endurance program retraining patients to use optimal muscle groups) in addition and compared to standard physiotherapy, massage and postural retraining. There was a clinically significant improvement in patients who had CTP. There was no placebo group.

A study from the Cochrane Database of systemic reviews titled “Non-invasive physical treatments for chronic/recurrent headache,” examined the efficacy of treatments such as spinal manipulation, stretching, therapeutic touch, transcutaneous electrical nerve stimulation (TENS), massage and amitriptyline (antidepressant). For the prophylactic treatment of chronic tension-type headache, amitriptyline was more effective than spinal manipulation during treatment. However, spinal manipulation was superior in the short term after cessation of both treatments. Other possible treatment options with weaker evidence of effectiveness were therapeutic touch; cranial electrotherapy; a combination of TENS and electrical neurotransmitter modulation; and a regimen of auto-massage, TENS and stretching. For episodic tension-type headache, there was evidence that adding spinal manipulation to massage was not effective.

For the prophylactic treatment of cervicogenic headache (related to neck injury), there was evidence that both neck exercise (low-intensity endurance training) and spinal manipulation were effective in the short and long term when compared to no treatment.

ACUPUNCTURE AND COMPLEMENTARY TREATMENTS

Acupuncture is a widely used therapy for a variety of medical problems, among them headache. While anecdotally patients appear to have significant improvement, rigorous clinical testing of efficacy is limited (based on Western Medicine methodology – randomized placebo controlled trials). Not surprisingly, there are no studies specific to the acoustic neuroma post-craniotomy headache population. However, several studies have been performed in tension headache patients.

A multicenter-randomized controlled trial of 270 patients published in the British Medical Journal compared two treatments, standard needle acupuncture and minimal acupuncture (minimal penetration at non-acupuncture sites - designed to be a sham procedure), to patients on a waiting list. There was no significant difference in improvement of the tension headache between the treatment groups, but both treatment groups did significantly better than the waiting list group. This suggests that a significant placebo effect was present. There are a tremendous number of non-traditional therapies for treatment of headache, which are beyond the scope of this publication.

In the chronic phase of pain management, the goal is to reduce the perception of pain. This can be accomplished with traditional or non-traditional methods. Even so, not all patients may experience a benefit with any given treatment. Eastern medicine therapies and their derivatives such as acupuncture, relaxation techniques, yoga, massage therapy and biofeedback may benefit some but not others, even if only by consistently providing a placebo effect.

STRESS REDUCTION AND ANTIDEPRESSANTS

Clearly, the occurrence of severe debilitating headache after acoustic neuroma surgery creates a tremendous amount of stress. This can exacerbate and perpetuate the headache and reaction to pain in an ever increasing cycle. In addition, chronic pain produces profound alterations in the chemistry of the brain, and this often is manifested as overt clinical depression. For these reasons, it is important that patients with severe headaches after acoustic neuroma surgery seek additional care to treat the psychosocial aspects of the disorder. Family, co-workers and health care providers need to understand the severity of these headaches and their associated impact on lifestyle and ability to function. Professional counseling is imperative when the headaches are producing disability or significant depression. Many antidepressant agents (e.g., Nortriptyline) also are excellent adjuncts to therapy of chronic pain and should be prescribed in conjunction with other therapies listed above.

MULTIDISCIPLINARY PAIN CENTER OR HEADACHE SPECIALIST

In the most treatment-resistant cases, it may be necessary to treat post acoustic neuroma surgery headaches in a multidisciplinary pain center. These centers are dedicated to treating chronic debilitating pain, and combine the talents of neurosurgeons, anesthesiologists, physical medicine specialists, psychiatrists and

physical therapists. Because acoustic neuroma headaches are caused by a variety of different factors, treating the problem fully frequently requires an intensive, combined approach such as that provided in a multidisciplinary pain center. Similarly, headache centers specializing in the treatment of intractable or otherwise difficult headache problems may be found in many cities and may be useful in difficult cases. These centers can be found via the National Headache Foundation at www.headaches.org and the American Headache Society at www.americanheadachesociety.org.

SUMMARY

In summary, short-term headaches that occur after acoustic neuroma surgery are common, can be severe and are difficult to treat when persistent. They have a profound impact upon the patient, and frequently produce significant disability, depression and a substantial decrease in quality of life. Although the specific causes of these headaches are not fully understood, there has been substantial progress in recent years in identifying several factors which may be involved in their development.

The best treatment for post acoustic neuroma headache is prevention. Most surgeons currently performing these procedures are aware of important preventative factors and take measures to minimize muscle incisions, replace skull bone whenever possible and limit the distribution of bone dust within the operative field.

When these preventative measures fail, an aggressive therapeutic regimen including steroids and non-steroid anti-inflammatory agents, local measures addressed to the neck muscles and psychological counseling should be instituted. If those measures fail, specialists in a multidisciplinary pain center should be consulted. By employing these treatment paradigms, some physicians have substantially reduced (but unfortunately not eliminated) the incidence and severity of headaches occurring after acoustic neuroma surgery. Tremendous advances in this area have been made in recent years, and hopefully subsequent discoveries will further reduce the impact of this devastating consequence to acoustic neuroma surgery.

Post Craniotomy headache diagnostic criteria adapted from the website of the International Headache Society (IHS)
 (http://www.ihs-classification.org/en/02_klassifikation/03_teil2/05.07.02_necktrauma.html):

	Acute	Chronic
ICD-10 code (IHS)	G44.880 (5.7.1)	G44.30 (5.7.2)
Diagnostic criteria	<ol style="list-style-type: none"> 1. Headache of variable intensity, maximal in the area of the craniotomy, fulfilling criteria 3 and 4 2. Craniotomy performed for a reason other than head trauma 3. Headache develops within 7 days after craniotomy 4. One or other of the following: <ol style="list-style-type: none"> a. Headache resolves <u>within 3 months</u> after craniotomy b. Headache persists but 3 months have not yet passed since craniotomy 	<ol style="list-style-type: none"> 1. Headache of variable intensity, maximal in the area of the craniotomy, fulfilling criteria 3 and 4 2. Craniotomy performed for a reason other than head trauma 3. Headache develops within 7 days after craniotomy 4. Headache persists <u>for >3 months</u> after craniotomy

From the IHS website:

Comments:

- *Immediate post-operative headache may occur in up to 80% of patients after craniotomy but resolves in most patients within 7 days. Fewer than one-quarter develop persistent (>3 months) headache related to the surgical procedure. Posterior fossa procedures, especially retrosigmoid/sub-occipital craniotomies performed for acoustic neuromas, are more likely to be associated with post-craniotomy headache.*
- *The pathogenesis of chronic headache after craniotomy is unclear but may involve meningeal inflammation, nerve entrapment, adhesion of muscle to dura or other mechanisms. Modifications in the operative procedure, including the use of osteoplastic cranioplasty, may lead to a reduction in the incidence of post-craniotomy headache by preventing adhesion of muscle and fascia to the underlying dura.*

WHAT IS THE ACOUSTIC NEUROMA ASSOCIATION (ANA)?

Acoustic Neuroma Association was founded in Carlisle, Pennsylvania, in 1981 by a recovered patient, Virginia Fickel Ehr. She found no patient information or patient support available when she had surgery for the removal of an acoustic neuroma in 1977. She resolved that future acoustic neuroma patients should have easy-to-read medical material about their condition, and support and comfort from each other. With the help of her physician, she contacted eight other patients and formed the organization.

The association is incorporated and is a 501(c)(3) non-profit organization. The patient-focused, member organization now serves close to 5,000 members, is governed by an all-patient Board of Directors and is operated by a small staff in metropolitan Atlanta, GA.

ANA membership benefits include receipt of a quarterly newsletter, patient information booklets, access to a network of local support groups, access to a list of acoustic neuroma patients willing to talk about their experience throughout the country, our website Member Section and an invitation to a biennial symposium on acoustic neuroma. Our exclusive website Member Section includes published medical journal articles on acoustic neuroma and all of our patient information booklets and newsletters and many symposium presentations. ANA also maintains an interactive website at www.ANAUSA.org with an ANA Discussion Forum.

ANA is patient-founded, patient-focused and patient-funded. ANA recommends treatment from a medical team with substantial acoustic neuroma experience. Although the association cannot recommend specific doctors, medical centers or medical procedures, guidelines for selecting a qualified medical professional can be found at the ANA website, www.ANAUSA.org. Now available on our website is a listing of medical resources. The physicians and organizations listed have self-reported data to meet criteria established by ANA for having substantial experience in treating acoustic neuromas. The listings should NOT in any way be construed as an endorsement or recommendation by ANA. It is every individual's responsibility to verify the qualifications, education and experience of any healthcare professional.

ANA PUBLICATIONS

You may want to order other ANA publications. Address your request to the following:

ANA
600 Peachtree Parkway, Suite 108
Cumming, GA 30041

Or phone us at 1-877-200-8211 or contact us by email at info@ANAUSA.org. Be sure to enclose the proper amount, as well as your name, address and zip code. Payment may also be made by check or by credit card using your Visa[®] or Mastercard[®]. You may also order any of these publications on our website at www.ANAUSA.org using your Visa[®] or Mastercard[®].

Booklets	Color	Price Each*
Acoustic Neuroma Basic Overview	Tan	\$1.50
Diagnosis: AN – What Next?	Peach	\$2.00
Eye Care after AN Surgery	Yellow	\$3.00
Facial Nerve and AN: Possible Damage & Rehabilitation	Gray	\$2.00
A Glimpse of the Brain	Green	\$1.50
Headache Associated with AN Treatment	Violet	\$2.00
Improving Balance Associated with AN	Red	\$3.00
Hearing Loss Rehabilitation for AN Patients	Teal	\$3.00

Newsletter Back Issues

Notes (quarterly publication) \$10.00 per mailing

***(For non-ANA members and multiple copies)**

Please add shipping and handling:

Orders	\$ 0.25	to \$15.00	add	\$ 4.00
Orders	\$15.01	to \$30.00	add	\$ 5.00
Orders	\$30.01	to \$45.00	add	\$ 6.00
Orders	\$45.01	to \$99.00	add	\$10.00
Orders	\$99.01	to \$200.00	add	\$12.00

Georgia residents, please add 7% Sales Tax

NOTE: ANA Members can view patient information booklets and newsletters online on our website at www.ANAUSA.org in our Member Section.

© Acoustic Neuroma Association, June 2012